

Transurethral resection of the ejaculatory ducts for treating ejaculatory symptoms

CHRISTOPHER W. JOHNSON, JONATHAN B. BINGHAM, ERIK T. GOLUBOFF and HARRY FISCH

Department of Urology, College of Physicians and Surgeons of Columbia University, New York, NY, USA

Accepted for publication 25 August 2004

OBJECTIVES

To report our experience with transurethral resection of the ejaculatory ducts (TURED) in infertile men with symptomatic ejaculatory duct obstruction (EDO).

PATIENTS AND METHODS

We retrospectively reviewed the operative cases of one urologist from 1995 to 2001, identifying 15 patients with symptomatic EDO who underwent TURED. These men had normal hormone levels and no other known genitourinary dysfunction. Investigations included a history, physical examination, semen analysis, semen culture, and high-

resolution transrectal ultrasonography. Responses to focused questions and semen analysis were evaluated after surgery.

RESULTS

Before surgery, all patients complained of a decrease in the volume of their ejaculate, 14 of 15 had a non-projectile ejaculation, nine had a genitourinary infection necessitating antibiotic treatment, and five had pain with orgasm. The mean ejaculate volume and total motile sperm count was 1.1 mL and 8.1 million sperm per ejaculate. After surgery, at a mean follow-up of 2 months, 10 men reported having projectile ejaculation, and eight reported a marked improvement in their

sensation of orgasm. Overall, 14 men reported a subjective improvement in their ejaculation. The average postoperative ejaculate volume was 2.3 mL and the total motile sperm count was 38.1 million per ejaculate.

CONCLUSIONS

Men with symptomatic EDO who underwent TURED showed improvements in their ejaculation, sensation of orgasm, semen analysis values and fertility.

KEYWORDS

ejaculatory duct obstruction, transurethral resection of ejaculatory duct, infertility.

INTRODUCTION

Ejaculatory duct obstruction (EDO) is a known cause of male factor infertility, and should be suspected in men with oligozoospermia, azoospermia, or low-volume, non-projectile ejaculation. Men with EDO might develop symptoms of dysuria, haematospermia, low-volume ejaculates, non-projectile ejaculation, pain on or after ejaculation, perineal or testicular pain, or low back pain [1]. The prevalence of EDO in the population is unknown, but it is estimated that it is the cause of azoospermia in $\approx 5\%$ of patients [2]. EDO is rare and has various causes; possible congenital and acquired causes include: congenital atresia, duct cysts, trauma, infection, inflammation and calculus formation [3,4]. Evidence of this process can be found by semen analysis and high-resolution TRUS. Before the advent of TRUS, EDO could only be confirmed by vasography [5].

The diagnosis of EDO is important for infertile men as it can be corrected by surgery. Transurethral resection of the ejaculatory duct (TURED) is the standard form of therapy,

but there is little published information on how the symptoms of EDO respond to therapy. To examine this question, we report our experience with TURED in men presenting with infertility who had ejaculatory symptoms associated with EDO.

PATIENTS AND METHODS

We retrospectively reviewed the operative log of one urologist (H.F.) from 1995 to 2001. Fifteen men were found to have symptomatic EDO, which was identified as the source of their infertility, and these men were subsequently treated with TURED. The preoperative symptoms included non-projectile ejaculation, a decrease in sensation of orgasm, and/or pain with ejaculation. Investigations included a focused history and physical examination, two or more semen analyses, a semen culture (with PCR analysis), and TRUS. On TRUS, each man was evaluated for prostatic calcifications, ejaculatory duct cysts and the diameter of the seminal vesicles. Seminal vesicles were considered dilated when they were ≥ 12 mm in diameter.

Each man was treated with TURED using a standard resecting loop in the midline of the proximal verumontanum (described in detail by Goluboff *et al.* [6], Fig. 1). A vasogram or seminal vesiculogram were not taken. Directly after resecting the EDO the prostate was massaged to show improved flow through the resected ejaculatory ducts, confirming successful treatment. The outcome of the operation was evaluated ≈ 2 months after surgery, and included focused questions about the symptoms of EDO, and a semen analysis.

The inclusion criteria for the study required that all men had at least one of the symptoms of EDO, bilaterally palpable vas deferens, normal hormone profiles (testosterone, oestradiol, FSH and LH), no other known genitourinary abnormality, and were treated with TURED.

RESULTS

Before surgery, 14 of 15 men had a non-projectile ejaculation, nine had a genitourinary infection necessitating

treatment with an antibiotic, four had pain with ejaculation, and two had haemospermia. The mean ejaculate volume and total motile sperm count was 1.1 mL and 8.1 million sperm per ejaculate. On TRUS, 12 men had prostatic calcifications, six had dilated seminal vesicles and five had ejaculatory duct cysts.

After surgery, at a mean follow-up of 2 months, 14 men reported a subjective improvement in their ejaculation, and resolution of their haemospermia and pain with ejaculation. They also noted a return to projectile ejaculation and an increase in the volume of their ejaculate. Ten men now reported having projectile ejaculation, eight reported a marked improvement in their sensation of orgasm, and two of the four men who complained of pain with ejaculation reported resolution of the pain. No men reported an exacerbation of their symptoms after TURED. The mean ejaculate volume increased to 2.3 mL and the total motile sperm count to 38.1 million per ejaculate. Four of the six men available for long-term follow-up reported successful paternity without assisted reproduction techniques. There were no complications associated with the procedure.

DISCUSSION

EDO is a rare cause of infertility, but it is essential to diagnose it, as it can be easily corrected with a minor cystoscopic procedure. Detecting EDO has become easier and less invasive with the development of high-resolution TRUS, which by itself has been shown to be very effective for identifying possible EDO [7,8]; it can show cysts or calcifications that might cause blockage, and identifies dilated seminal vesicles. In the present study, seminal vesicles were considered to be dilated if they were ≥ 12 mm in diameter. Several groups have attempted to establish 15 mm as the threshold for significant dilation, but this has not been universally accepted [6,9–11]. After EDO was suspected, these men underwent TURED. At the time of TURED, patency of the ejaculatory ducts was confirmed by a prostatic massage and by identifying expressed seminal fluid from the ejaculatory ducts.

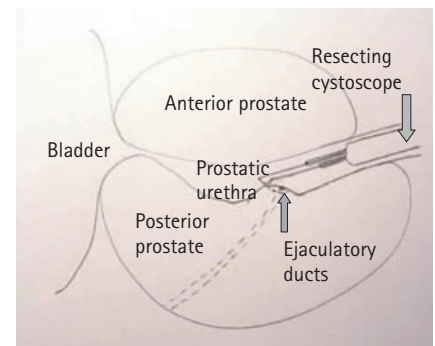
Since 1973, TURED has become the standard treatment for EDO [12], as it is associated with a low risk of complications.

Rare complications include rectal injury, external sphincter injury, bladder neck injury with resulting retrograde ejaculation, and the possibility of urine reflux into the ejaculatory ducts [4,13]. In the present series there were no complications, and nor did Pryor and Hendry [3] report any. Turek *et al.* [2] had complications in 20% of their patients, and Farley and Barnes [12] reported recurrent stricture formation in about half their patients. The complication profiles can vary widely. The only other technique that has been used for treating EDO is balloon dilatation of the EDO, which has met with mixed results and is usually reserved for EDO with extraprostatic obstruction [14].

There are no published reports on the symptomatology of EDO and how men subjectively respond to treatment. We chose to focus on this issue. Fifteen men were included in the study and 14 reported an improvement in their EDO after TURED. There are several points to be drawn from this. It is possible that most cases of EDO result from a partial blockage and not total obstruction. The incidence of bilateral total occlusion of the ejaculatory ducts is $<1\%$ in infertile men [12,15], so it is likely that many men with EDO have partial obstruction that might develop into complete EDO [16]. This would allow for a range of presentations of EDO. Although not all men are left infertile from EDO, most are symptomatic. Importantly, the present study evaluated only infertile men, and it is likely that many fertile men have the symptoms of EDO but have not reported them. This could be evaluated in future studies that include fertile men with similar symptoms. While examining this, it would also be necessary to validate the long-term durability of TURED for proximal EDO. It would be useful to use established validated questionnaires to evaluate these patients' symptoms.

EDO affects more than a man's fertility. As with any body system, there is often discomfort with any blockage, as a result of stimulation of pressure receptors in the affected lumen, and this is a possible cause in men with EDO that could explain the physical pain reported by some. However, men with symptoms of EDO often also have a psychological component to their problem; they often have non-projectile ejaculations and low-volume ejaculates, which could be very disturbing to them, and which might be perceived as a sexual malfunction and as a threat to their masculinity. Infertility issues

FIG. 1. Transverse view of TURED



aside, the symptoms of EDO can have a major impact on sexual satisfaction and should therefore be addressed.

In conclusion, EDO is a very treatable disease that can be cured with a simple procedure. This is the first study to focus on the symptomatic improvement of men who have TURED for relieving proximal EDO. This therapy has a positive impact not only on fertility, but also on sexual satisfaction. Long-term prospective trials are necessary to validate the durability of this therapy and its effect on the symptoms of EDO. This initial experience suggests that TURED can have potential new applications for infertile and possibly fertile men with symptomatic proximal EDO.

CONFLICT OF INTEREST

None declared.

REFERENCES

- 1 Fisch H, Kang YM, Johnson CW, Goluboff ET. Ejaculatory duct obstruction. *Curr Opin Urol* 2002; **12**: 509–15
- 2 Turek PJ, Magana JO, Lipshultz LI. Semen parameters before and after transurethral surgery for ejaculatory duct obstruction. *J Urol* 1996; **155**: 1291–3
- 3 Pryor JP, Hendry WF. Ejaculatory duct obstruction in subfertile males: analysis of 87 patients. *Fertil Steril* 1991; **56**: 725–30
- 4 Goldwasser BZ, Weinerth JL, Carson CC 3rd. Ejaculatory duct obstruction: the case for aggressive diagnosis and treatment. *J Urol* 1985; **134**: 964–6
- 5 Paick JS, Kim SH, Kim SW. Ejaculatory

- duct obstruction in infertile men. *BJU Int* 2000; **85**: 720–4
- 6 **Goluboff ET, Stifelman MD, Fisch H.** Ejaculatory duct obstruction in the infertile male. *Urology* 1995; **45**: 925–31
 - 7 **Kuligowska E, Baker CE, Oates RD.** Male infertility: role of transrectal US in diagnosis and management. *Radiology* 1992; **185**: 353–60
 - 8 **Cornud F, Belin X, Delafontaine D, Amar T, Hélénon O, Moreau JF.** Imaging of obstructive azoospermia. *Eur Radiol* 1997; **7**: 1079–85
 - 9 **Meacham RB, Hellerstein DK, Lipshultz LI.** Evaluation and treatment of ejaculatory duct obstruction in the infertile male. *Fertil Steril* 1993; **59**: 393–7
 - 10 **Jarow JP.** Transrectal ultrasonography of infertile men. *Fertil Steril* 1993; **60**: 1035–9
 - 11 **Littrup PJ, Lee F, McLeary RD, Wu D, Lee A, Kumasaka GH.** Transrectal US of the seminal vesicles and ejaculatory ducts: clinical correlation. *Radiology* 1988; **168**: 625–8
 - 12 **Farley S, Barnes R.** Stenosis of ejaculatory ducts treated by endoscopic resection. *J Urol* 1973; **109**: 664–6
 - 13 **Goluboff ET, Kaplan SA, Fisch H.** Seminal vesicle urinary reflux as a complication of transurethral resection of the ejaculatory ducts. *J Urol* 1995; **153**: 1234–5
 - 14 **Pryor JP, Schlegel PN.** Management of ejaculatory duct obstruction. In Lipshultz LI, Howard SS, eds, *Infertility in the Male*. 3rd edn. Chapter 21. St. Louis: Mosby, 1997
 - 15 **Jarow JP, Espeland MA, Lipshultz LI.** Evaluation of the azoospermic patient. *J Urol* 1989; **142**: 62–5
 - 16 **Nagler HM, Rotman M, Zoltan E, Fisch H.** The natural history of partial ejaculatory duct obstruction. *J Urol* 2002; **167**: 253–4

Correspondence: Harry Fisch, 944 Park Avenue, 1st Floor, New York, NY 10028–0319, USA.
e-mail: harryfisch@aol.com

Abbreviations: TURED, transurethral resection of the ejaculatory ducts; EDO, ejaculatory duct obstruction.